

CLINICAL IMAGE

Unusual Presentation of Primary B-Cell Lymphoma

SALAHADDIN UBAID¹, IMAN ALI²

¹Department of Cardiology, University Hospitals Coventry and Warwickshire, Coventry, UK ²Department of Rheumatology, New Cross Hospital Wolverhampton UK

A young female patient presented with an incidental finding of a painless skin mass in the anterior chest wall, which was later confirmed to be advanced primary mediastinal B-cell lymphoma. Our patient was asymptomatic in spite of the disease being at an advanced stage. This is unusual for this type of tumours

Key words: mass, mediastinum, lymphoma

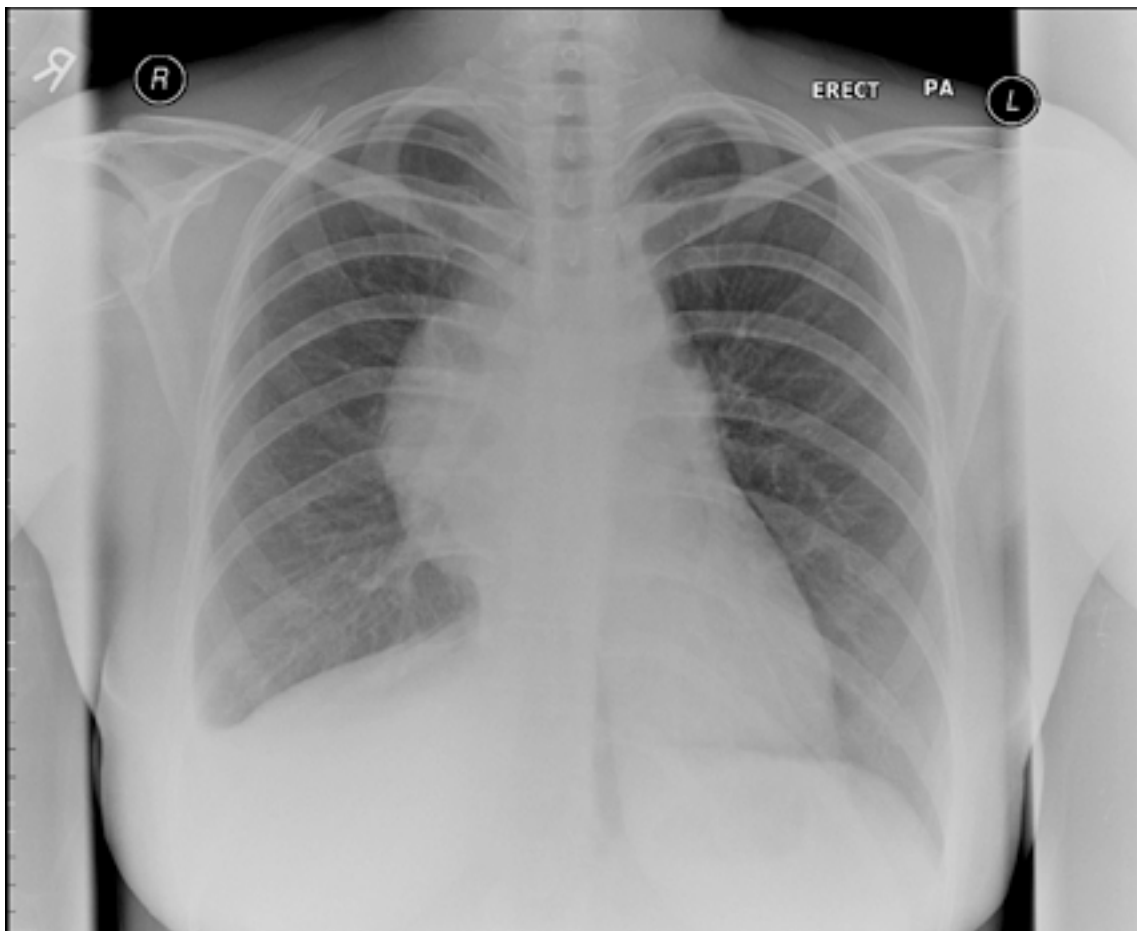


Figure 1, A Chest X-ray showing widened mediastinum.

Correspondance:

Salahaddin Ubaid

Department of Cardiology, University Hospitals Coventry and Warwickshire, Coventry, UK

E-mail: salahaddin.ubaid@uhcw.nhs.uk

Tel: (+44) 7581243435

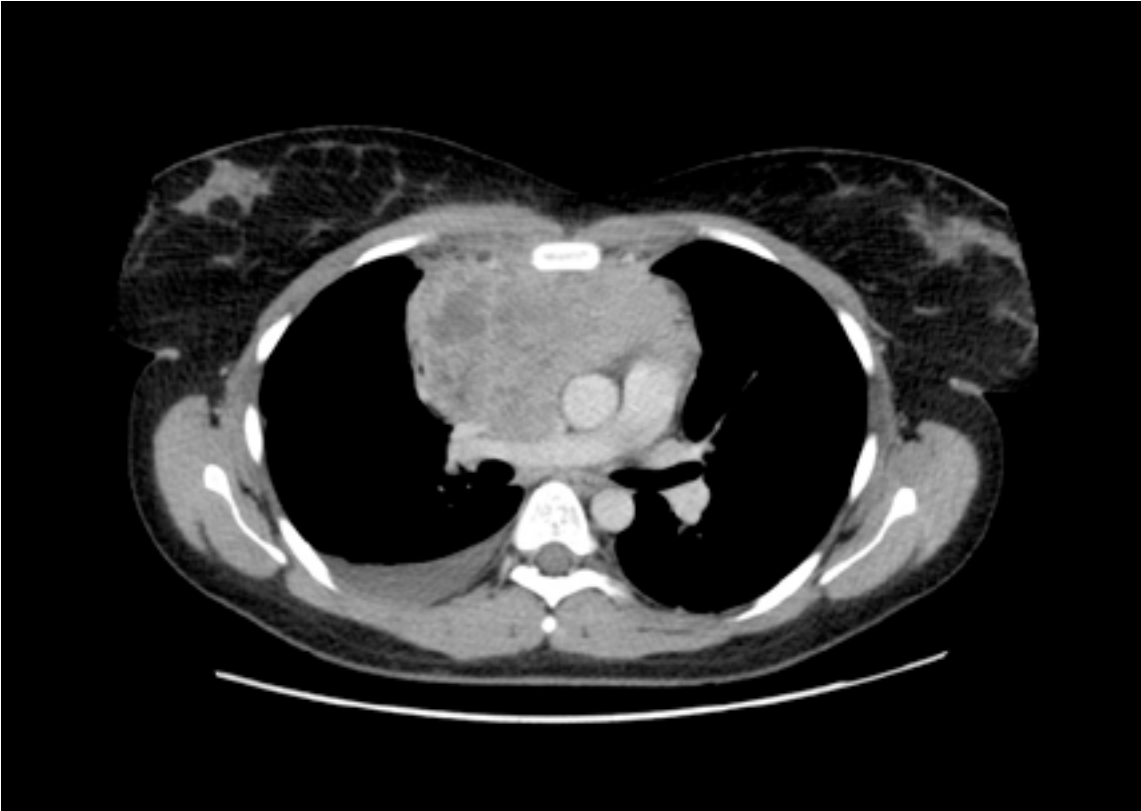

Figure 2, CT Scan of Thorax showing anterior mediastinal mass. Right sided pleural effusion also noted.