

CASE REPORT

Bowel herniation: a rare complication of jejunostomy

KUN-CHOU HSIEH¹, SHIH-HSIEN YANG¹ and YU-JEN CHENG¹

¹Division of Thoracic Surgery, Department of Surgery, E-Da Hospital, Kaohsiung, Taiwan

ABSTRACT

A jejunostomy can provide adequate parenteral nutrition support for patients who oral intake is difficult. Jejunostomy-related complications are commonly seen, however they rarely result in repeat laparotomy. Herein, we report a rare complication in which a long segment of bowel herniation from the abdominal stoma with dislodged feeding tube. Because the bowel mucosa was congestive and swelling, an emergent laparotomy for jejunum reduction and jejunum segmental resection was done. After surgery, this patient recovered well and discharged two weeks later. The discussion will be focused on the mechanism and management about this complication.

Key words: bowel herniation, jejunostomy, peristomal dermatitis.

INTRODUCTION

Jejunostomy is a simple procedure for those who oral intake is difficult. However, dermatitis around stoma is a common complication of jejunostomy. It is caused by irritation from bowel juice or food. Most of dermatitis could be treated by topical ointment which can provide better protection from a large amount of bowel juice.¹ Without adequate care, those stomas will gradually be eroded by bowel juice to become a large one which enteral nutrition is not feasible. Under this condition, the size of stomas will be enlarged in a vicious cycle due to protein deficiency.² Now, we presented a rare complication about a long segment of jejunum herniated through an enlarged stoma with severe dermatitis.

CASE REPORT

A 73-year-old male patient presented to our emergency room with epigastric pain and coffee-ground vomitus after swallowing half a bottle of detergent containing hydrogen chloride in January 2011. He had chronic obstructive pulmonary disease and major depression after his wife died. The initial arterial blood gas showed pH level = 7.325, HCO₃⁻ = 16.7mEq/L, Base excess = -8.2mmol/L. The abdomen on left decubitus X-ray showed lack of obvious intraperitoneal free air. Panendoscopy revealed diffuse desquamation and ulcer in the esophagus and black blood in the whole stomach. Because of uncorrected metabolic acidosis refractory to a large amount of fluid resuscitation, exploratory laparotomy was performed to confirm organ necrosis. For whole layer necrosis at the stomach with perforation at the

fundus and partial necrosis at the esophagus, total gastrectomy and subtotal esophagectomy were performed. Besides, cervical esophagostomy for saliva draining and jejunostomy with Stamm technique for postoperative nutritional support were done.³ During hospitalization, vocal cord swelling and poor airway hygiene led to tracheostomy for respiratory care. Two months later, he was transferred to healthcare unit for continuous respiratory care.

Because of persistent poor physical and psychiatric conditions, reconstruction of the esophagus with colon interposition was not proper to him. Therefore, we replaced regularly a 16 French nasogastric tube into the stoma every one month. The dermatitis around the stoma progressively became worse due to erosion by bowel juice. We applied corticosteroid ointment for skin care and tried sutures to decrease the leakage. However, the patient lost follow-up for six months.

He was brought to the emergency room again in February 2012. A long segment of bowel herniation from the jejunostoma was found by his family (Fig. 1).

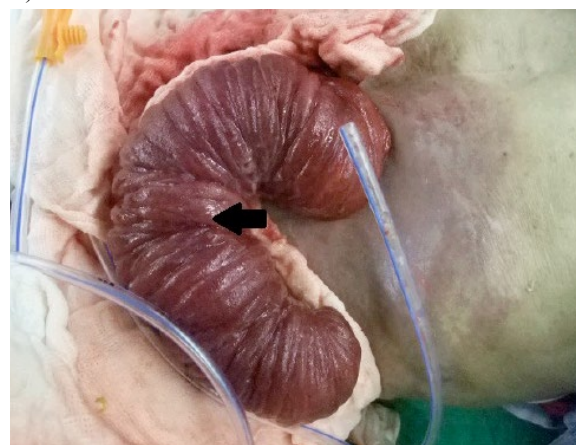


Figure 1, Post A long segment of bowel herniated through the jejunostomy. The mucosa became dark red (arrow).

Correspondence:

Yu-Jen Cheng

Division of General Thoracic Surgery, E-Da Hospital, Kaohsiung, Taiwan.

Email: yujen.cheng@msa.hinet.net

The nasogastric tube was also dislodged along with bowel herniation. The bowel mucosa was externally exposed and congestive. For keep moisture, the herniated bowel was covered with gauze pads. The complete blood count and electrolyte were within normal range except low hemoglobin (Hb = 11.4). The plain abdomen had no free air or dilated bowel loop. There were not peritoneal sign at abdominal palpation. Manual reduction of the hernia was considered difficult and hazardous due to tissue swelling. Because of being afraid of strangulation, an emergency laparotomy to reduce the hernia was suggested. The peritoneal cavity was approached by midline laparotomy along the prior operative scar. There was not turbid ascites or feces in the abdomen. The small bowel did not show gangrene change. The hernia was easily reduced by withdrawing the intra-abdomen bowel. The bowel mucosa immediately turned normal color and motility following reduction. Because the stoma and the exit of underlying jejunum were enlarged to 3cm in diameter (Fig. 2), it is impossible to keep enteral feeding.

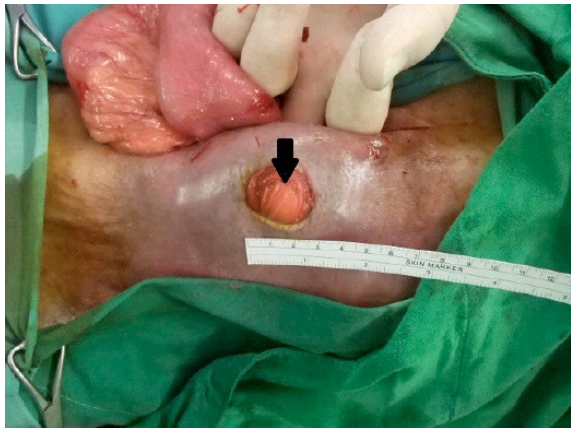


Figure 2, After reduction of the hernia, the diameter of stoma measured to 3 cm (arrow).

Therefore, the prior jejunostoma was taken down followed by segmental bowel resection and redo a jejunostomy with Witzel technique.³ The patient recovered well and discharged two weeks later. The patient had no other complication about jejunostomy after one year follow-up.

DISCUSSION

Jejunostomy can provide nutritional support after upper alimentary tract surgery and any disease resulting in difficulty in swallowing.⁴ This procedure may result in many minor complications, such as diarrhea, wound infection, and peristomal dermatitis. However, there are still some major complications like necrotizing fasciitis, small bowel perforation, small bowel volvulus around the jejunostomy tube, and jejunostomy-jejunal intussusceptions, which lead to repeat laparotomy.^{5,6,7,8,9} Bowel juice leakage is troublesome to stoma care. The stoma will be enlarged without good care. A rare complication about a long segment of small bowel herniating through an enlarged jeju-

nostoma was found in our institute. The complication has not previously been published in the literature to the best of our knowledge.

Most of bowel hernias were present in the form of bowel loop passing through the weak muscle point. However, the stoma hernia in our case was present with mucosa layer exposure. This special type of bowel herniation was more common in end colostomy.¹⁰ But, it was rare to occurred in jejunostomy. The possible mechanism was that the bowel mucosa was movable during bowel peristalsis but the serosa was peritonealized. Therefore, it was likely that the mucosal layer would be herniated through a large jejunostomy.

There were many factors were suspected to relate to enlargement of the stoma in this case, including malnutrition, increased intra-abdominal pressure from strenuous cough, and bowel juice leakage from the stoma leading to peristomal skin erosion. Peristomal skin affected by bowel juice is problematic but often overlooked.¹¹ Corticosteroid ointments are often applied for peristomal dermatitis.¹ Additionally, topical sucralfate had been reported as an effective therapy for the management of resistant peristomal dermatitis.¹² Although there was not definite report, our clinical observation found that the type selection of jejunostomy may play a role in preventing bile leakage. Because of tunnel formation in Witzel technique, the stoma was away from the exit of jejunum. However, the bile leakage directly passed through the stoma to invade the surrounding skin in Stamm technique. For this reason, the Witzel technique seems to be a better choice for long term enteral feeding.

Based on these reasons, patients should prevent stoma from enlarging by the above methods especially for those with extreme malnutrition. When bowel herniation occurs, laparotomy instead of manual method for bowel reduction is a safer method because the mucosal layer was very congestive under incarceration.

CONCLUSION

Feeding jejunostomy can provide enteral nutrition for those who cannot feed orally. It is important to keep the stoma from peristomal dermatitis affected by bowel juice leakage which can result in skin erosion thereby progressively enlarging the size of the stoma. If dermatitis occurred, topical steroid or sucralfate are beneficial to them. If bowel mucosa herniates through the jejunostomy, the stoma and underlying bowel exit will become too large to feed milk. So, the laparotomy for reduction and segmental resection should be considered.

REFERENCES

1. Lyon CC, Smith AJ, Griffiths CE. Peristomal dermatoses: a novel indication for topical steroid lotions. *J Am Acad Dermatol* 2000; 43:679-682.
2. Cheryl T, Patricia F. *Nutrients and Wound Healing*:

Still Searching for the Magic Bullet. *Nutr Clin Pract* 2005; 20: 331-347.

3. Robert M. Zollinger Jr, Author, E. Christopher Ellison, eds. *Zollinger's Atlas of Surgical Operations*. 9th ed. New York: McGraw-Hill; 2011.

4. Pramesh CS, Mistry RC, Deshpande RK. Enteral feeding access with feeding jejunostomy is advisable after esophagectomy. *Eur J Cardiothorac Surg* 2003; 23: 648-649.

5. Sriram K. Necrotizing fasciitis following feeding jejunostomy. *J Parenter Enteral Nutr* 1988; 12: 322.

6. Sonawane RN, Thombare MM, Kumar A. Technical complications of feeding jejunostomy: a critical analysis. *Trop Gastroenterol* 1997; 18: 127-128.

7. Halkic N, Guerid S, Blanchard A. Small-bowel perforation: a consequence of feeding jejunostomy. *Can J Surg* 2005; 48: 161-162.

Bowel herniation: a rare complication of jejunostomy

8. Sivasankar A, Johnson M, Jeswanth S. Small bowel volvulus around feeding jejunostomy tube. *Indian J Gastroenterol* 2005; 24: 272-273.

9. Chandan C, Argha C, Shibajyoti G. Jejuno-ileal intussusception: An unusual complication of feeding jejunostomy. *Arch Intern Surg* 2013; 3: 52-54.

10. B. Mahjoubi, A. Moghimi, R. Mirzaei, A. Bijari. Evaluation of the end colostomy complications and the risk factors influencing them in Iranian patients. *Colorectal Dis* 2005; 7: 582-587.

11. Agarwal S, Ehrlich A. Stoma dermatitis: prevalent but often overlooked. *Dermatitis* 2010; 21: 138-147.

12. A.H.Hayashi, H.Y.C. Lau, D.A.Gillis. Topical sulfacate: Effective therapy for the management of resistant peristomal and perineal excoriation. *J Pediatr Surg* 1991; 26: 1279-1281.