

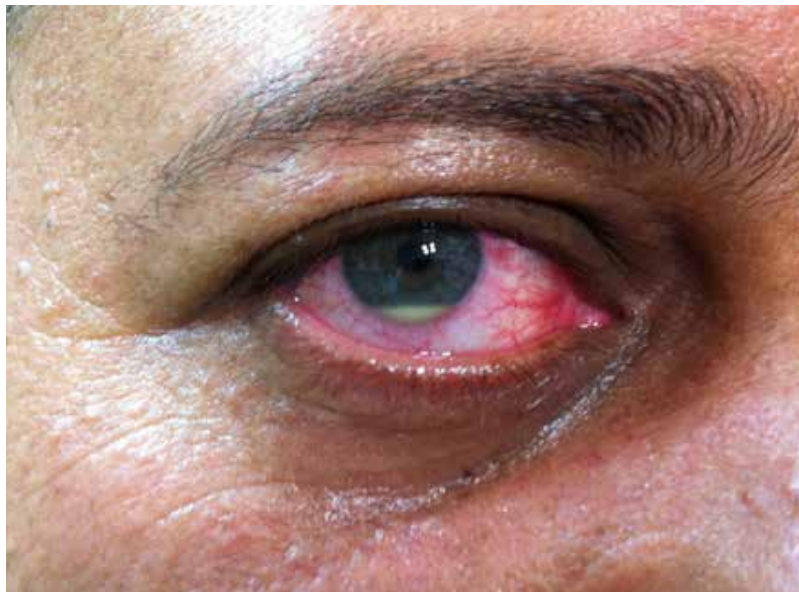
CLINICAL IMAGE

Unilateral hypopyon in Behçet's disease after binge drinking

GOLBARG MEHRPOOR¹, MOHAMMADMEHDI AZIMZADEH²

¹Internist, Assistant professor of medicine, Alborz university of Medical Science

²Medical Reasercher, Alborz university of Medical Science



A 42-year-old male, known case of Behçet's disease, attended the rheumatology clinic complaining red eye, blurred vision, pain and photophobia. The symptoms were developed a few hours after binge drinking. He had history of Behçet's disease from 8 years ago and was treated with cyclosporine, meth

otrexate, colchicines and the other anti-inflammatory drugs and he was in complete remission for more than two years. Physical examination revealed typical hypopyon and anterior uveitis in his right eye. The left eye was quiet, with no evidence of intra-ocular inflammation. Oral or genital aphthi were absent and the other physical exams were unremarkable.

Correspondence:

Dr. Golbarg Mehrpoor
Internist, Assistant professor of medicine, Alborz
University of Medical Science, Karaj, Iran
E-mail: golbargmehrpoor@yahoo.com